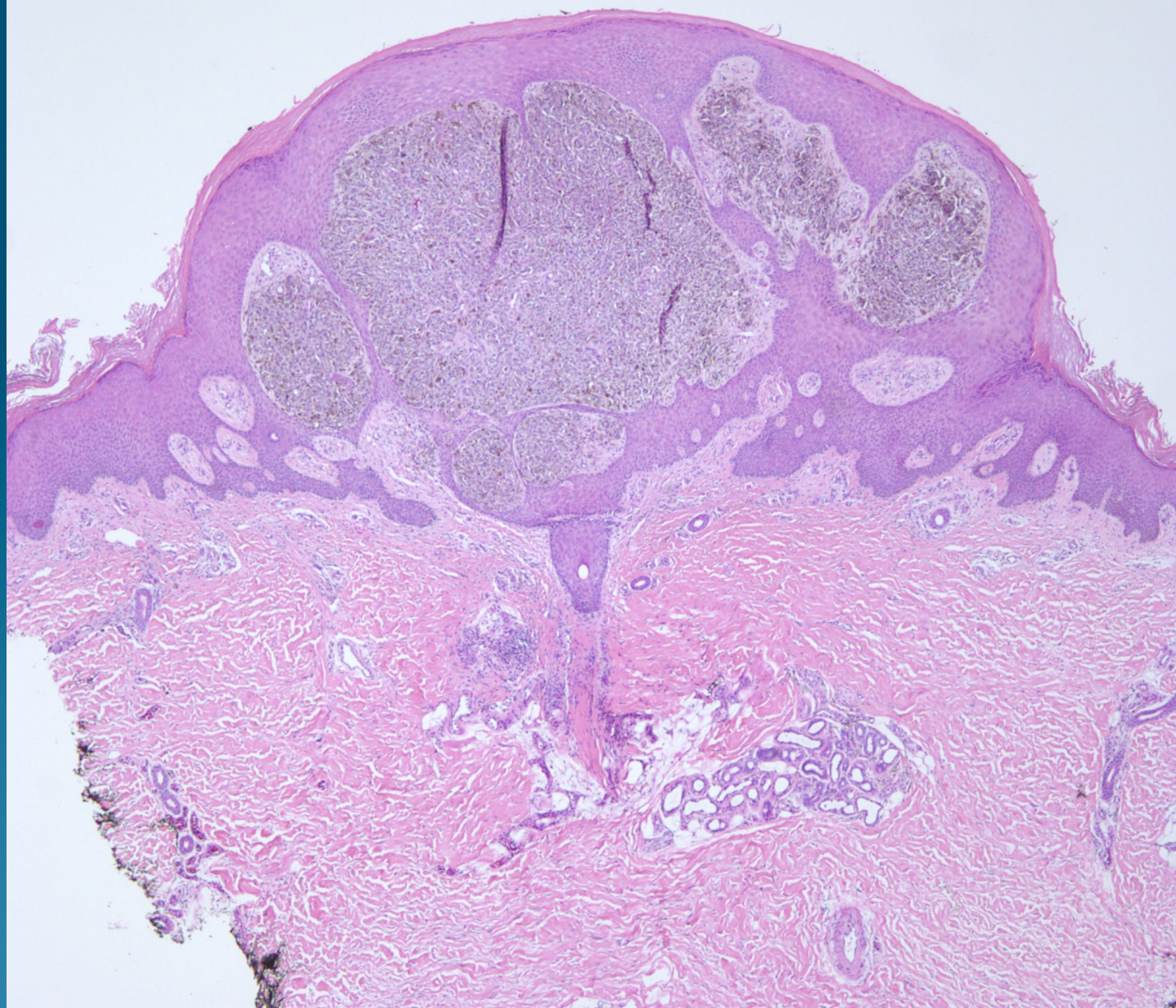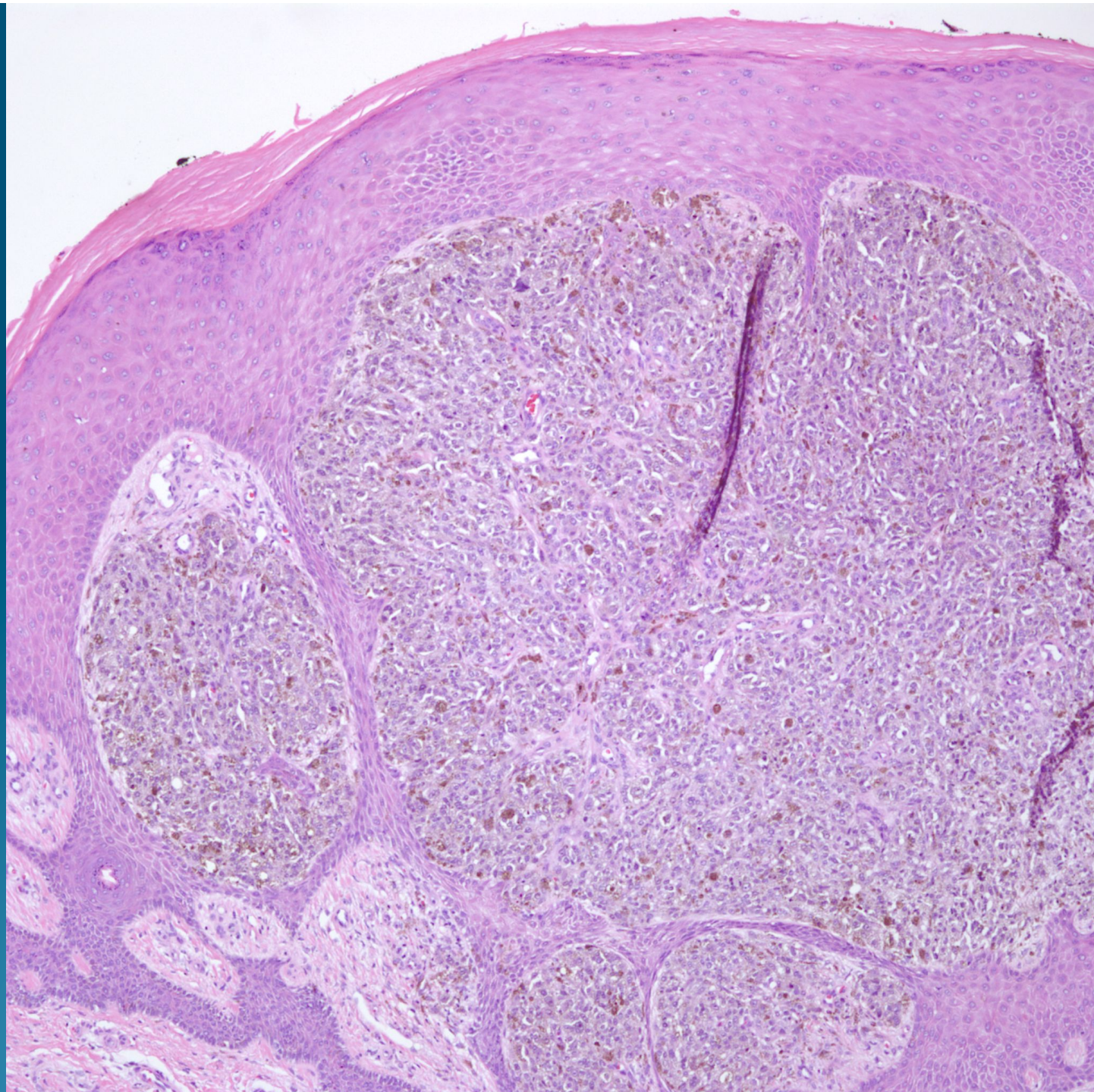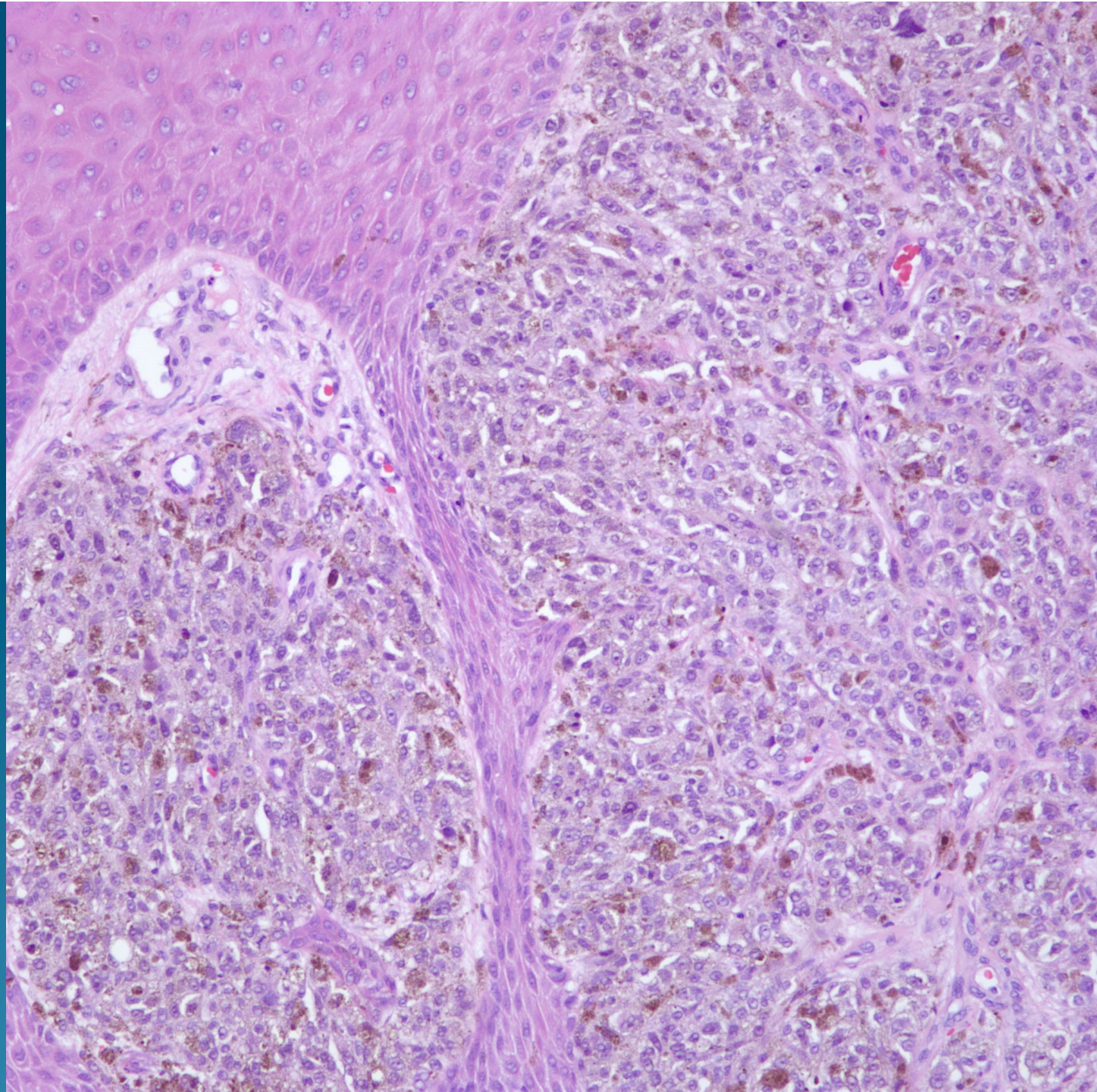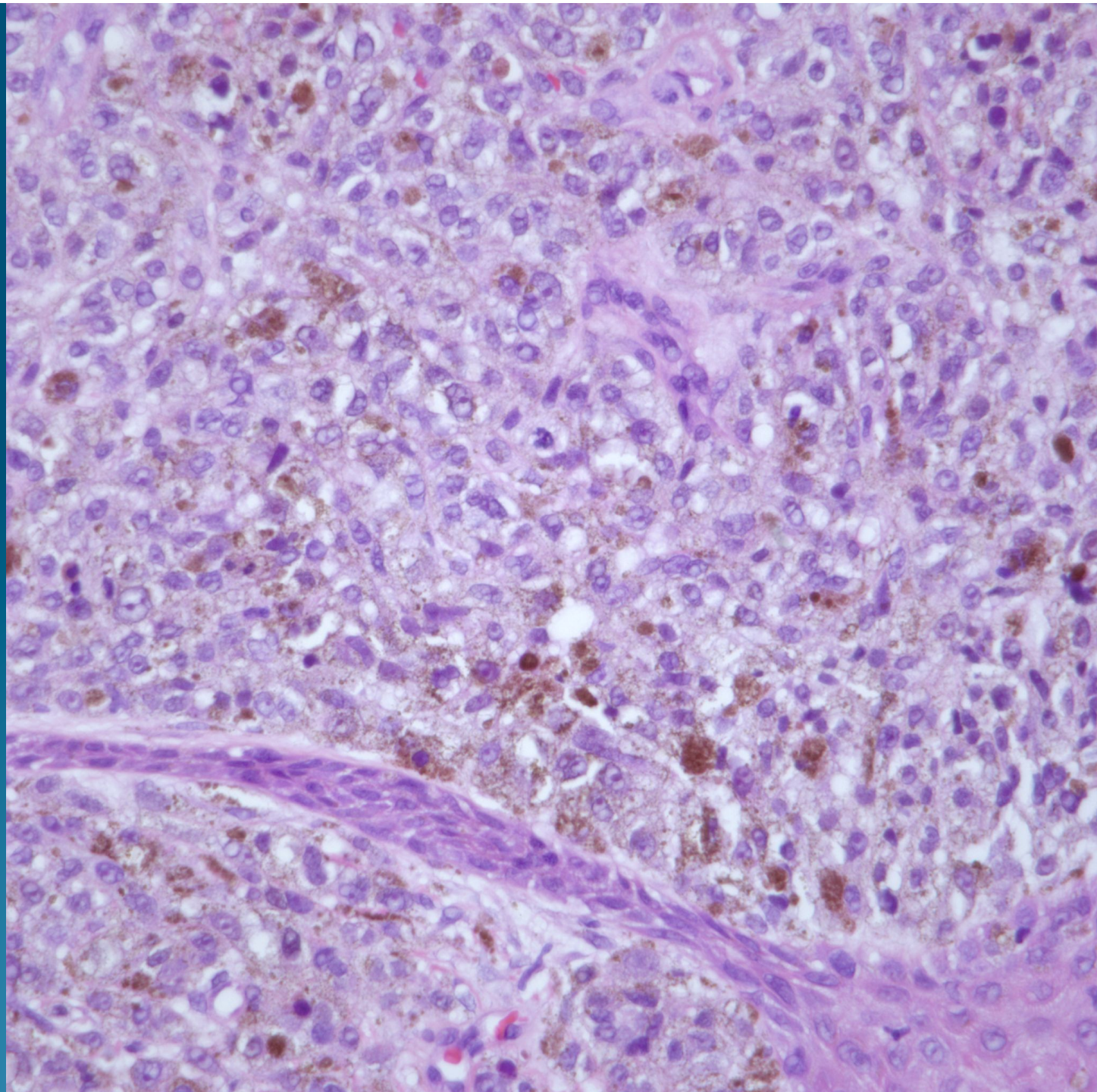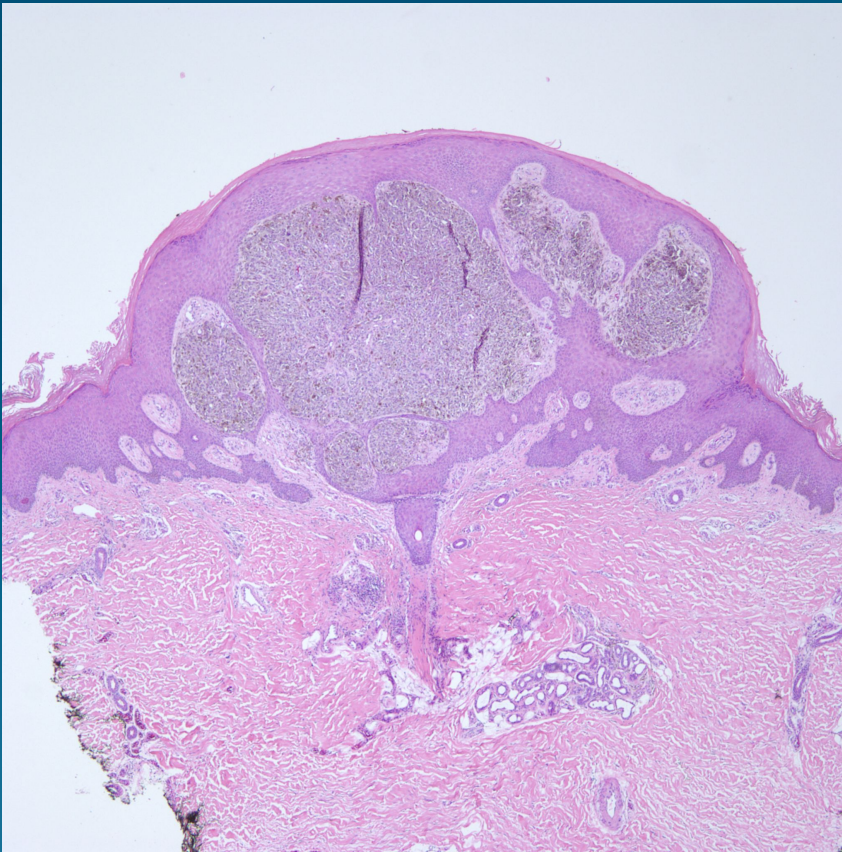


What is the best diagnosis?

- A. Melanoma metastatic to the skin
- B. Primary nodular melanoma
- C. Cellular blue nevus
- D. Deep penetrating nevus
- E. Pigmented nodular basal cell carcinoma

Melanoma Metastatic to the Skin

Pearls



- Predominately dermal based nodule of malignant melanocytes
- Variable epidermal involvement but usually dermal component predominates over epidermal
- Beware low power architecture resembles benign nevus